

COVID-19 associated parotitis: A case report

Jennifer Fisher, Derek L. Monette, Krupa R. Patel, Brendan P. Kelley, Maura Kennedy

PII: S0735-6757(20)30549-0

DOI: <https://doi.org/10.1016/j.ajem.2020.06.059>

Reference: YAJEM 159146

To appear in: *American Journal of Emergency Medicine*

Received date: 10 June 2020

Accepted date: 21 June 2020

Please cite this article as: J. Fisher, D.L. Monette, K.R. Patel, et al., COVID-19 associated parotitis: A case report, *American Journal of Emergency Medicine* (2020), <https://doi.org/10.1016/j.ajem.2020.06.059>

This is a PDF file of an article that has undergone enhancements after acceptance, such as the addition of a cover page and metadata, and formatting for readability, but it is not yet the definitive version of record. This version will undergo additional copyediting, typesetting and review before it is published in its final form, but we are providing this version to give early visibility of the article. Please note that, during the production process, errors may be discovered which could affect the content, and all legal disclaimers that apply to the journal pertain.

COVID-19 associated parotitis: a case report

Jennifer Fisher, PA-C¹; Derek L. Monette, MD²; Krupa R. Patel MD³; Brendan P. Kelley, MD, MSc⁴; Maura Kennedy MD²

¹ Departments of Emergency Medicine, Massachusetts General Hospital, Boston, MA

² Departments of Emergency Medicine, Massachusetts General Hospital and Harvard Medical School, Boston, MA

³ Department of Otolaryngology-Head & Neck Surgery, Massachusetts Eye & Ear, Harvard Medical School, Boston, MA

⁴ Departments of Radiology, Massachusetts General Hospital and Harvard Medical School, Boston, MA

Corresponding Author:

Maura Kennedy, MD

5 Emerson Place, 119B

Boston, MA 02114

Tel.: (617) 643-0276

Fax: (617) 754-2350

email: mkennedy8@partners.org

All authors report no conflict of interest. This research did not receive any specific grant from funding agencies in the public, commercial, or not-for-profit sectors.

Keywords: parotitis, coronavirus, COVID-19

Word count, body: 799

Journal Pre-proof

COVID-19 associated parotitis: a case report

Abstract:

As the 2019 coronavirus pandemic has unfolded, an increasing number of atypical presentations of COVID-19 have been reported. As patients with COVID-19 often present to emergency departments for initial care, it is important that emergency clinicians are familiar with these atypical presentations in order to prevent disease transmission. We present a case of a 21-year-old woman diagnosed in our ED with COVID-19 associated parotitis and review the epidemiology and management of parotitis. We discuss the importance of considering COVID-19 in the differential of parotitis and other viral-associated syndromes and emphasize the importance of donning personal protective equipment during the initial evaluation.

1. Introduction

The 2019 coronavirus pandemic presents healthcare workers (HCWs) in the emergency department (ED) with numerous clinical and diagnostic challenges. Currently, there are 6.6 million cases worldwide and 1.8 million cases in the United States (US) [1]. The most commonly reported symptoms include fever, dry cough, and fatigue [2]. However, an increasing number of asymptomatic infections and atypical presentations have been recognized, including gastrointestinal, neurological, and dermatologic complaints [2-4]. As patients with COVID-19 often present first to EDs for evaluation, it is critical ED clinicians are familiar with these atypical presentations in order to safely triage patients and prevent disease transmission. We present a case report of a woman infected with COVID-19 and diagnosed with parotitis.

2. Case Report

A 21 year-old-female presented to the ED with left-sided facial and neck swelling. She presented to another ED eight days prior with fever, cough, and dyspnea and diagnosed with COVID-19. Despite improvement of her respiratory symptoms, she developed progressive unilateral facial and neck swelling causing subjective malocclusion and trismus. On review of systems, she reported decreased oral intake but denied persistent fevers, dental pain or facial weakness.

On examination, the patient had normal vital signs and moderate left-sided cheek, preauricular, and submandibular swelling without erythema, induration or fluctuance. The intraoral exam was normal, with no purulent drainage expressible from Stensen's duct and normal occlusion. The rest of her physical exam was unremarkable. Imaging and blood laboratory values were obtained to work-up a differential that included infectious parotitis, sialolithiasis, salivary gland abscess, and neoplasm. Laboratory values were notable for a leukopenia to 3,170/uL without lymphopenia. Computed tomography (CT) of the neck demonstrated: diffuse asymmetric enlargement and swelling of the left parotid gland without an obstructing stone, mass, or abscess; periparotid inflammatory fat stranding; and free fluid extending into the left submandibular, submental, and parapharyngeal spaces and along the left sternocleidomastoid and strap muscles (Figures 1 and 2). Otolaryngology was consulted given the extension of free fluid into surrounding anatomical spaces. Her history, exam and CT findings were felt to be most consistent with uncomplicated acute infectious parotitis. Her sensation of malocclusion was attributed to inflammation surrounding her muscles of mastication. The patient was prescribed a course of amoxicillin/clavulanate to

treat a possible concomitant bacterial parotitis and advised to apply warm compresses, massage the gland, use sialagogues to increase salivary flow and stay hydrated.

3. Discussion

A variety of microorganisms can cause salivary gland infections and the parotid gland is most commonly affected [5,6]. Though paramyxovirus is the classic cause of viral parotitis, incidence of mumps has decreased 99% in the US due to widespread vaccination [5]. A variety of other respiratory viruses can lead to non-mumps parotitis, including enteroviruses and influenza, parainfluenza, coxsackie, and Epstein-Barr viruses [5,6]. Typically, viral parotitis is characterized by a prodrome of flu-like symptoms followed 2-4 days later by gradual swelling of the bilateral parotid glands, though unilateral involvement is seen in up to 25% of cases [6,7]. Acute suppurative parotitis is characterized by sudden onset of unilateral pain and swelling of the parotid gland [6,7]. Stasis of salivary flow secondary to dehydration is believed to facilitate bacterial migration into the parotid gland orifice and retrograde infection of the gland by oral flora [6,7]. Physical exam findings in suppurative parotitis include induration and tenderness of the parotid gland and purulent discharge from the duct orifice with massaging the gland [6,7].

Our patient had a mixed presentation. Unilateral involvement and decreased oral intake favor a bacterial etiology; however, she did not have erythema or induration and her laboratory studies demonstrated leukopenia, not leukocytosis. While we believe this was a viral-induced parotitis, given the unilateral presentation we treated her for possible bacterial co-infection.

At the time we evaluated this patient there were no reports of COVID-19 associated parotitis. Fortunately, our patient had already been diagnosed with COVID-19, otherwise it is possible we may not have recognized facial swelling as a symptom of COVID-19 and evaluated her without proper personal protection equipment (PPE). Other cases of COVID-19 parotitis and intraparotid lymphadenitis have recently been published [8,9]. This adds to an expanding literature of atypical presentations of COVID-19. The immune dysregulation and inflammation caused by COVID-19 infection can affect numerous organs. Guillian-Barré syndrome (GBS) [10] and cutaneous small vessel vasculitis resulting in palpable purpuric toe lesions [11] have been reported in association with COVID-19 infection. More recently, a multisystem inflammatory syndrome has been described in children infected with COVID-19, causing a Kawasaki-like illness associated with myocardial dysfunction and shock [12]. It is critical ED clinicians stay informed of the growing spectrum of clinical presentations of COVID-19 to ensure appropriate clinical care and use of PPE to minimize disease transmission.

4. Conclusion

Atypical presentations of COVID-19 are being increasingly recognized. ED clinicians must have a high suspicion for COVID-19 among any patient presenting with infectious symptoms or viral-associated illnesses and don available PPE accordingly for the initial evaluation.

References

1. World Health Organization. *Coronavirus Disease (COVID-19) Situation Report-138*.; 2020. https://www.who.int/docs/default-source/coronaviruse/situation-reports/20200606-covid-19-sitrep-138.pdf?sfvrsn=c8abfb17_4. Accessed June 6, 2020.
2. Zhu J, Ji P, Pang J, et al. Clinical characteristics of 3,062 COVID-19 patients: a meta-analysis. *J Med Virol*. April 2020. doi:10.1002/jmv.25884
3. Mao L, Jin H, Wang M, et al. Neurologic Manifestations of Hospitalized Patients with Coronavirus Disease 2019 in Wuhan, China. *JAMA Neurol*. 2020. doi:10.1001/jamaneurol.2020.1127
4. Gianotti R, Veraldi S, Recalcati S, et al. Cutaneous clinico-pathological findings in three covid-19-positive patients observed in the metropolitan area of Milan, Italy. *Acta Derm Venereol*. 2020;100(8). doi:10.2340/00015555-3490
5. Wilson KF, Meier JD, Ward PD. Salivary gland disorders. *Am Fam Physician*. 2014;89(11):882-888. doi:10.1016/j.mcna.2014.08.008
6. Lau RK, Turner MD. Viral mumps: Increasing occurrences in the vaccinated population. *Oral Surg Oral Med Oral Pathol Oral Radiol*. 2019;128:386-392. doi:10.1016/j.oooo.2019.06.012
7. Kessler AT, Bhatt AA. Review of the Major and Minor Salivary Glands, Part 1: Anatomy, Infectious, and Inflammatory Processes. *J Clin Imaging Sci*. 2018;8:47. doi:10.4103/jcis.jcis_45_18
8. Lechien JR, Chetrit A, Chekkoury-Idrissi Y, et al. Parotitis-Like Symptoms Associated with COVID-19, France, March-April 2020. *Emerg Infect Dis*. 2020;26(9). doi:10.3201/eid2609.202059
9. Capaccio P, Pignataro L, Corbellino M, Popescu-Dutruit S, Torretta S. Acute Parotitis: A Possible Precocious Clinical Manifestation of SARS-CoV-2 Infection? *Otolaryngol Head Neck Surg*. May 2020:019459982092699. doi:10.1177/0194599820926992
10. Zhao H, Shen D, Zhou H, Liu J, Chen S. Guillain-Barré syndrome associated with SARS-CoV-2 infection: causality or coincidence? *Lancet Neurol*. 2020;19:383-384. doi:10.1016/S1474-4422(20)30109-5
11. Mayor-Ibarguren A, Feito-Rodriguez M, Quintana Castanedo L, Ruiz-Bravo E, Montero Vega D, Herranz-Pinto P. Cutaneous small vessel vasculitis secondary to COVID-19 infection: A case report. *J Eur Acad Dermatol Venereol*. May 2020. doi:10.1111/jdv.16670
12. Chiotos K, Bassiri H, Behrens EM, et al. Multisystem Inflammatory Syndrome in Children during the COVID-19 pandemic: a case series. *J Pediatric Infect Dis Soc*. 2020. doi:10.1093/JPIDS/PIAA069

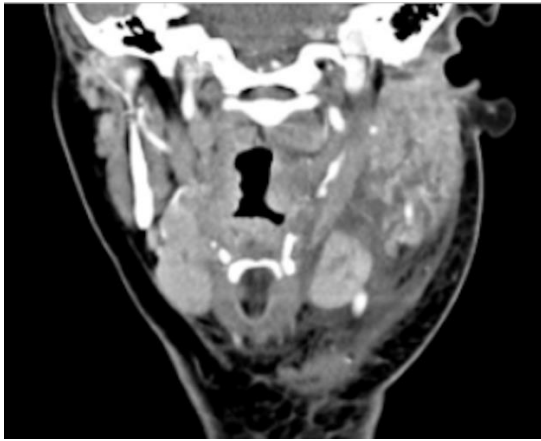

Figure 1: Axial image from a contrast enhanced CT of the neck demonstrates diffuse asymmetric swelling of the left parotid gland with surrounding fat stranding without associated obstructing stone, mass, or abscess.

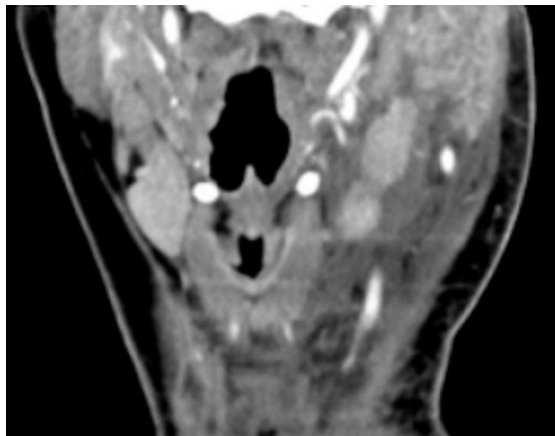


Figure 2: Coronal image from a contrast enhanced CT of the neck demonstrates diffuse asymmetric swelling of the left parotid gland with surrounding fat stranding without evidence of an obstructing stone, mass, or abscess. The acute periparotid inflammatory change is associated with thickening of the overlying platysma muscle, enlargement of adjacent lymph nodes, and extensive free fluid tracking throughout the left neck.